

Biology

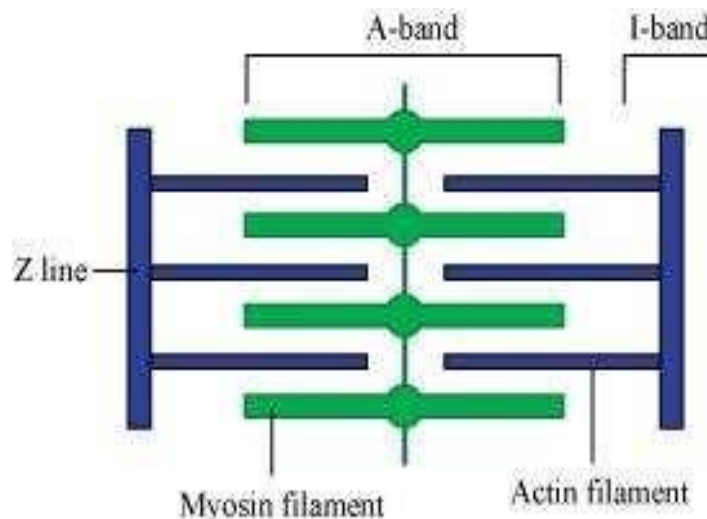
(Chapter – 20)(Locomotion and Movement) (Class – XI)

Question 1:

Draw the diagram of a sarcomere of skeletal muscle showing different regions.

Answer 1:

The diagrammatic representation of a sarcomere is as follows:



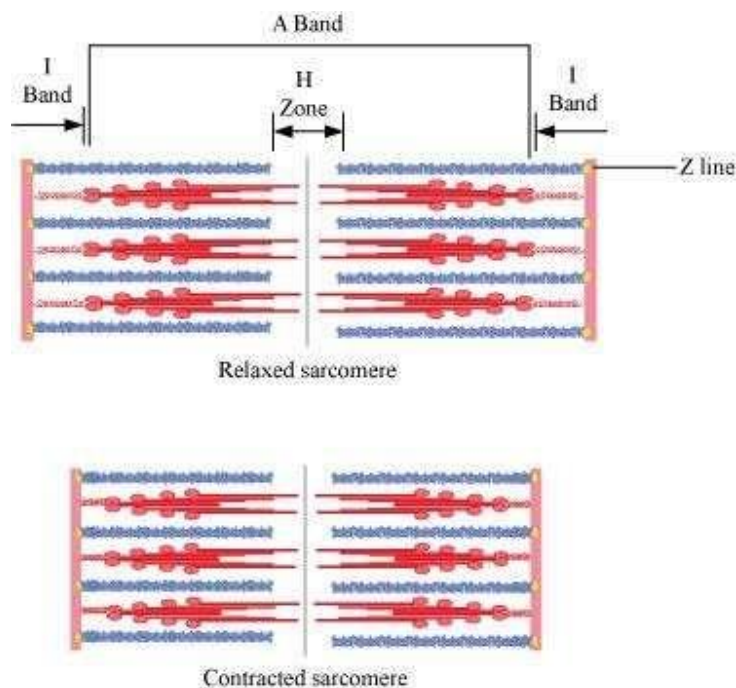
Question 2:

Define sliding filament theory of muscle contraction.

Answer 2:

The sliding filament theory explains the process of muscle contraction during which the thin filaments slide over the thick filaments, which shortens the myofibril. Each muscle fibre has an alternate light and dark band, which contains a special contractile protein, called actin and myosin respectively. Actin is a thin contractile protein present in the light band and is known as the I-band, whereas myosin is a thick contractile protein present in the dark band and is known as the A-band. There is an elastic fibre called z line that bisects each I-band. The thin filament is firmly anchored to the z line. The central part of the thick filament that is not overlapped by the thin filament is known as the H-zone. During muscle contraction, the myosin heads or cross bridges come in close contact with the thin filaments. As a result, the thin filaments are pulled towards the middle of the sarcomere. The Z line attached to the actin filaments is also pulled leading to the shortening of the sarcomere. Hence, the length of the band remains constant as its original length and the I-band shortens and the H-zone disappears.





Question 3:

Describe the important steps in muscle contraction.

Answer 3:

During skeletal muscle contraction, the thick filament slides over the thin filament by a repeated binding and releases myosin along the filament. This whole process occurs in a sequential manner.

Step 1: Muscle contraction is initiated by signals that travel along the axon and reach the neuromuscular junction or motor end plate. Neuromuscular junction is a junction between a neuron and the sarcolemma of the muscle fibre. As a result, Acetylcholine (a neurotransmitter) is released into the synaptic cleft by generating an action potential in sarcolemma.

Step 2: The generation of this action potential releases calcium ions from the sarcoplasmic reticulum in the sarcoplasm.

Step 3: The increased calcium ions in the sarcoplasm leads to the activation of actin sites. Calcium ions bind to the troponin on actin filaments and remove the tropomyosin, wrapped around actin filaments. Hence, active actin sites are exposed and this allows myosin heads to attach to this site.

Step 4: In this stage, the myosin head attaches to the exposed site of actin and forms cross bridges by utilizing energy from ATP hydrolysis. The actin filaments are pulled. As a result, the H-zone reduces. It is at this stage that the contraction of the muscle occurs.

Step 5: After muscle contraction, the myosin head pulls the actin filament and releases ADP along with inorganic phosphate. ATP molecules bind and detach myosin and the cross bridges are broken.

Stage 6: This process of formation and breaking down of cross bridges continues until there is a drop in the stimulus, which causes an increase in calcium. As a result, the concentration of calcium ions decreases, thereby masking the actin filaments and leading to muscle relaxation.

Question 4:

Write true or false. If false change the statement so that it is true.

- (a) Actin is present in thin filament
- (b) H-zone of striated muscle fibre represents both thick and thin filaments.
- (c) Human skeleton has 206 bones.
- (d) There are 11 pairs of ribs in man.
- (e) Sternum is present on the ventral side of the body.

Answer 4:

- (a) True
- (b) False
- (c) True
- (d) False
- (e) True

Question 5:

Write the difference between:

- (a) Actin and Myosin
- (b) Red and White muscles
- (c) Pectoral and Pelvic girdle

Answer 5:

- (a) Actin and Myosin

	Actin		Myosin
1	Actin is a thin contractile protein.	1	Myosin is a thick contractile protein.
2.	It is present in light bands and is called an isotropic band.	2	It is present in dark bands and is called an anisotropic band.



(b) Red and White muscles

	Red muscle fibre		White muscle fibre
1	Red muscle fibres are thin and smaller in size.	1	White muscle fibres are thick and larger in size.
2	They are red in colour as they contain large amounts of myoglobin.	2	They are white in colour as they contain small amounts of myoglobin.
3	They contain numerous mitochondria.	3	They contain less number of mitochondria.
4	They carry out slow and sustained contractions for a long period.	4	They carry out fast work for short duration.
5	They provide energy by aerobic respiration.	5	They provide energy by anaerobic respiration.

(c) Pectoral and Pelvic girdle

	Pectoral girdle		Pelvic girdle
1	It is a skeletal support from where the forelimbs of vertebrates are attached.	1	It is a skeletal support from where the hind limbs of vertebrates are attached.
2	It is composed of two bones namely, clavicle or collar bones and scapula or shoulder bone.	2	It is composed of three bones, upper ilium, inner pubic, and ischium.

Question 6:

Match Column I with Column II:

	Column I		Column II
(a)	Smooth muscle	(i)	Myoglobin
(b)	Tropomyosin	(ii)	Thin filament
(c)	Red muscle	(iii)	Sutures
(d)	Skull	(iv)	Involuntary

Answer 6:

	Column I		Column II
(a)	Smooth muscle	(iv)	Involuntary
(b)	Tropomyosin	(ii)	Thin filament
(c)	Red muscle	(i)	Myoglobin
(d)	Skull	(iii)	Sutures



Question 7:

What are the different types of movements exhibited by the cells of human body?

Answer 7:

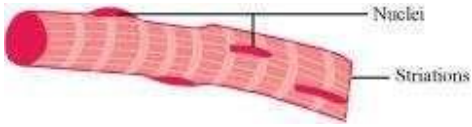
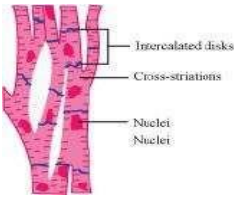
Movement is a characteristic feature of living organisms. The different types of movement exhibited by cells of the human body are:

- Amoeboid movement: Leucocytes present in the blood show amoeboid movement. During tissue damage, these blood cells move from the circulatory system towards the injury site to initiate an immune response.
- Ciliary movement: Reproductive cells such as sperms and ova show ciliary movement. The passage of ova through the fallopian tube towards the uterus is facilitated by this movement.
- Muscular movement: Muscle cells show muscular movement.

Question 8:

How do you distinguish between a skeletal muscle and a cardiac muscle?

Answer 8:

	Skeletal muscle		Cardiac muscle
1.	The cells of skeletal muscles are unbranched.	1.	The cells of cardiac muscles are branched.
2.	Intercalated disks are absent.	2.	The cells are joined with one another by intercalated disks that help in coordination or synchronization of the heart beat.
3.	Alternate light and dark bands are present.	3.	Faint bands are present.
4.	They are voluntary muscles.	4.	They are involuntary muscles.
5.	They contract rapidly and get fatigued in a short span of time.	5.	They contract rapidly but do not get fatigued easily.
6.	They are present in body parts such as the legs, tongue, hands, etc.	6.	These muscles are present in the heart and control the contraction and relaxation of the heart.
			



Question 9:

Name the type of joint between the following:

- (a) atlas/axis
- (b) carpal/metacarpal of thumb
- (c) between phalanges
- (d) femur/acetabulum
- (e) between cranial bones
- (f) between pubic bones in the pelvic girdle

Answer 9:

- (a) atlas/axis: Pivotal joint
- (b) carpal/metacarpal of thumb: Saddle joint
- (c) between phalanges: Hinge joint
- (d) femur/acetabulum: Ball and socket joint
- (e) between cranial bones: Fibrous joint
- (f) between pubic bones in the pelvic girdle: Ball and socket joint

Question 10:

Fill in the blank spaces:

- (a) All mammals (except a few) have _____ cervical vertebra.
- (b) The number of phalanges in each limb of human is _____
- (c) Thin filament of myofibril contains 2 'F' actins and two other proteins namely _____ and _____.
- (d) In a muscle fibre Ca^{++} is stored in _____
- (e) _____ and _____ pairs of ribs are called floating ribs.
- (f) The human cranium is made of _____ bones.

Answer 10:

- (a) All mammals (except a few) have Seven cervical vertebra.
- (b) The number of phalanges in each limb of a human is 14.
- (c) Thin filament of myofibril contains 2 'F' actins and two other proteins, namely tropomyosin and troponin.
- (d) In a muscle fibre, Ca^{++} is stored in the sarcoplasmic reticulum.
- (e) 11th and 12th pairs of ribs are called floating ribs.
- (f) The human cranium is made up of eight bones.